

# Transanal Open Hemorrhoidopexy

F. Pakravan, M.D.<sup>1</sup> • C. Helmes, M.D.<sup>1</sup> • C. Baeten, M.D., Ph.D.<sup>2</sup>

<sup>1</sup> Coloproktologisches Zentrum Düsseldorf, Düsseldorf, Germany

<sup>2</sup> Department of Surgery, University Hospital Maastricht (azM), Maastricht, The Netherlands

**INTRODUCTION:** Despite all developments in the recent years, the choice of an adequate treatment for hemorrhoids remains a problem. The hemorrhoidopexy as described by Longo and the Doppler-guided hemorrhoidal artery ligation follow a concept different from the excision and destruction techniques from earlier years. In both techniques, the hemorrhoidal tissue is preserved, as it may be important for anal sensation and continence. The high costs of the circular stapler gun and the Doppler methods can probably be overcome by the proposed technique, a transanal open hemorrhoidopexy, while simultaneously preserving hemorrhoidal tissues.

**METHODS:** Between November 2006 and May 2007, 38 patients with third-degree hemorrhoids were treated with open transanal hemorrhoidopexy. All patients were positioned in the lithotomy position and operated under general anesthesia; the anal mucosa was stitched to the rectal wall with four Z-stitches after removal of a small rectal mucosa flap about 4 cm from the dentate line. The four stitches were circumferentially positioned at equal distances. Postoperatively, the patients followed a fiber-rich diet for one week.

**RESULTS:** Most patients (n = 32, 84 percent) were without any complaint upon follow-up at one week. Six patients (16 percent) experienced pain and were treated with oral analgesics. One patient (3 percent) experienced minor bleeding that stopped spontaneously. After one month follow-up, 34 patients (89 percent) had no symptom complaints. Two patients (5 percent) experienced segmental prolapse and two patients (5 percent) had remaining pruritus. No patient needed another intervention.

**CONCLUSION:** The proposed operation, transanal open hemorrhoidopexy, appears to be an effective technique. The procedure can be performed under direct vision and

is very cost effective compared to the other hemorrhoidal tissue-sparing procedures.

**KEY WORDS:** Hemorrhoidopexy; Hemorrhoids; Suture technique.

Continuing complaints of hemorrhoidal prolapse following earlier elastic band ligations or other first-line treatments of third-degree and fourth-degree hemorrhoids leave surgeons with difficult choices for pursuing treatment. The most common operation has been the hemorrhoidectomy in which the prolapsing hemorrhoidal tissue is excised, with or without closure of the wounds. These operations are very painful in the first weeks. Recent pathophysiologic insight proposes that elastic and muscular fibers in the anal canal are disrupted allowing hemorrhoidal tissue to slide downward, forming a prolapse.<sup>1-3</sup> The Longo technique leaves the hemorrhoidal tissue intact but elevates the tissue back to its original location. The results of this operation are good and reduce patients' postoperative pain scores considerably. The technique is well established but has a few problems: the operation has to be performed blindly since the circular stapler precludes visualization of the tissue that will be resected, bleeding from the stapled anastomosis is very common, and the costs of the equipment are high at 400 Euro in Germany which is approximately 600 US dollars.

Another recently described technique is the Doppler-guided hemorrhoidal artery ligation. The hemorrhoidal tissue is preserved and the arterial inflow is stopped by ligation of the artery branches guided by Doppler ultrasound. A flaw in the technique is that the prolapse is not directly addressed and the equipment often gives problems. The costs are less than Longo's stapler hemorrhoidopexy but still considerable.

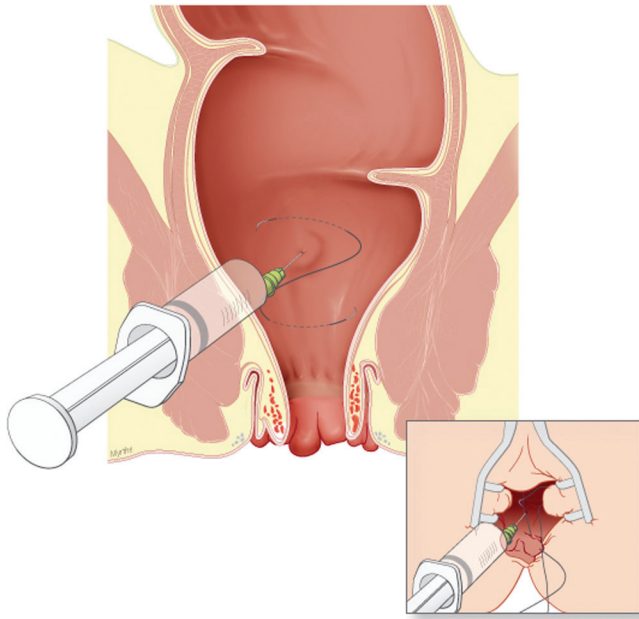
Transanal open hemorrhoidopexy described in this paper is a new technique which is much less costly and spares hemorrhoid tissue.

## METHODS

Between November 2006 and May 2007, transanal open hemorrhoidopexy was performed as a pilot study in

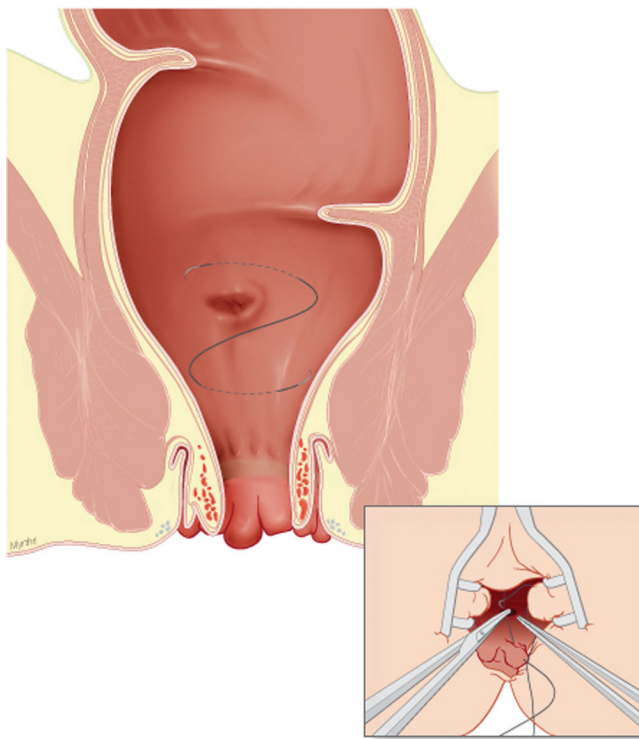
Address of correspondence: C. Baeten, M.D., Ph.D., Department of Surgery AZM Maastricht, Postbox 5800, 6202AZ Maastricht, The Netherlands. E-mail: c.baeten@mumc.nl

Dis Colon Rectum 2009; 52: 503-506  
DOI: 10.1007/DCR.0b013e318197d703  
©The ASCRS 2009

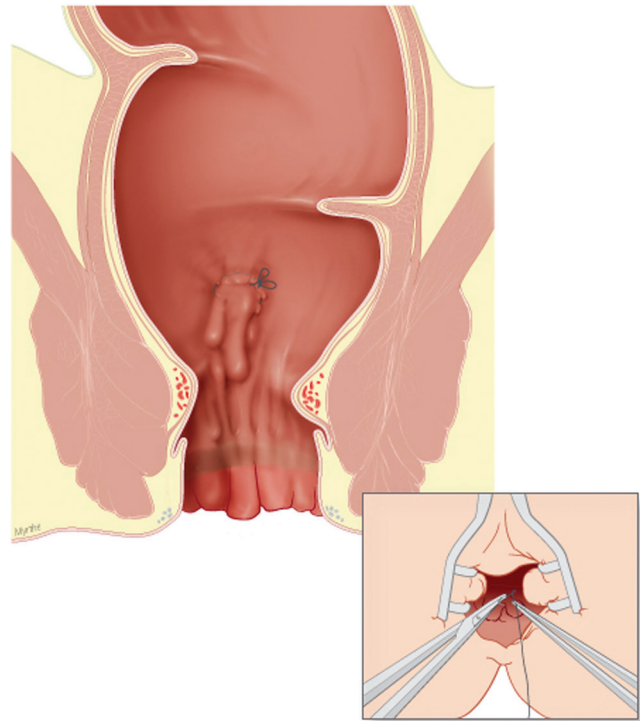


**FIGURE 1.** Z-shaped suture approximately 4 cm above the dentate line. Submucosal injection of adrenaline solution (1:100,000).

38 consecutive patients with third and fourth-degree hemorrhoids. All patients were preoperatively questioned about bleeding, anal pain, prolapse, and itching. After anoscopic examination, all patients underwent anal manometry and a colonoscopy.



**FIGURE 2.** Excision of 1 cm [square] mucosa.



**FIGURE 3.** Lifting of the hemorrhoidal tissue by tightening of the Z-shaped suture.

All patients received a preoperative enema. No antibiotics were given. Patients were operated on under general anesthesia in the lithotomy position. A Parks' retractor was used to give access to the anorectum. At 4 cm from the dentate line, a stitch through the rectal wall was placed and then at the upper level of the hemorrhoidal tissue using 2-0 Vicryl sutures. Before knotting this Z-suture, a 1-cm strip of mucosa between both stitches was excised after infiltration with adrenaline solution (1:100,000 dilutions). Then the Z-suture was tightened, pulling up the prolapsing hemorrhoid high into the anal canal. This procedure was repeated in three to four quadrants of the anus as needed at the point of maximal prolapse. The four sutures were mainly located at 2, 5, 7, and 11 o'clock (Figs. 1–3).

Postoperatively the patients received a fiber-rich diet. No postoperative antibiotics were given, and in cases of pain the patients received diclofenac and metamizole. Follow-up visits were scheduled at one, two, four, and seven days postoperatively and later after one and six months.

## RESULTS

Thirty-eight patients were included (17 males, 45 percent and 21 females, 55 percent) with a mean (standard deviation, SD) age of 52 years (SD, 15). The mean (SD) follow-up was 157 days (SD, 68). All patients had circular or segmental prolapsing hemorrhoids. Seventeen patients

experienced blood loss, 13 patients complained of thrombosis, 10 patients experienced pain, 9 patients reported soiling, 7 patients were constipated, 7 patients reported diarrhea, and 14 patients complained of itching. All patients underwent a transanal open hemorrhoidopexy and 1 to 4 quadrants were treated. The mean (SD) operating time was 15 minutes (16). No perioperative complications occurred.

Immediately after surgery, 32 patients (84 percent) were pain free. In six patients, severe pain was treated with diclofenac and metamizole. In one patient, minor bleeding occurred that was caused by a dehiscence of one suture but the bleeding required no further treatment.

After one month, most patients ( $n = 34$ , 89 percent) were free of pain. Two patients (5 percent) still had perianal pruritus and two patients (5 percent) showed a small residual segmental prolapse. These patients were treated conservatively with diet and pelvic floor physiotherapy. After 6 months of follow-up, no patients required additional surgery.

## DISCUSSION

Complaints attributable to hemorrhoids are very common in the Western world. Estimates suggest 50 percent of all people older than 50 years have hemorrhoid symptoms at least for some time. The causes of hemorrhoidal disease are multiple, but most are attributable to difficult passage of stool or constipation.<sup>4</sup> Based on anatomic and radiologic investigations by Stelzner *et al.*<sup>5,6</sup> and Thomson,<sup>2,3</sup> hemorrhoids are seen as an arteriovenous network sliding downward in the anal canal. The most often prolapsing regions are typically located at 3, 7, and 11 o'clock in the lithotomy position. In these locations, muscle and elastic fibers next to hemorrhoidal vessels are visible. These fibers are responsible for the connection between mucosa and submucosa to the muscular rectal wall.<sup>7,8</sup> The hemorrhoidal tissue is a normal anatomic entity, very important for fecal continence. When the connecting fibers are disrupted, the hemorrhoidal tissue slides downward the anal canal and causes patients' symptomatic complaints. The term hemorrhoid implicates that there are always symptoms. A hemorrhoid is the presence of normal tissue at the wrong location. The pain can be explained by the traction of the nonsensitive sliding hemorrhoidal tissue at the highly sensitive anal skin. The blood loss is caused by irritation of the mucosal layer. Severe bleeding is only seen when the stowed hemorrhoidal vessels are disrupted.<sup>2,4,9</sup> About 10 percent of patients with hemorrhoids eventually need surgical therapy.<sup>10</sup>

The traditional operation is the open (Milligan-Morgan) or the closed (Ferguson-Parks) hemorrhoidectomy in which the prolapsing hemorrhoidal tissue is resected with the adjacent anoderm. The normal tissue that contributes to continence is partly removed and the

open or sutured wounds usually result in a painful postoperative period. The resection of the prolapse means that the complaints from this prolapse will disappear.<sup>11</sup> Almost all newer surgical techniques rely on destruction of superfluous hemorrhoidal tissue by heat (electrocautery, laser), freezing (cryo probe), ligation (Barron banding), or sclerosing (injections). A recent technique is the Doppler-guided ligation of the hemorrhoidal arteries as described by Morinaga *et al.*<sup>12</sup> In this technique, the hemorrhoidal tissue remains untouched and postoperative pain is prevented.

The stapled hemorrhoidectomy as described by Longo<sup>13-16</sup> also leaves hemorrhoidal tissues untouched and prevents postoperative pain. This procedure should correctly be named stapled hemorrhoidopexy since hemorrhoidal tissue is not resected, but elevated and fixed inside the anorectum. This procedure became popular since it results in little or no postoperative pain compared to classic hemorrhoidectomy. Many trials have been published<sup>16-25</sup> confirming the pain-sparing effects. The first postoperative defecation occurs earlier than in hemorrhoidectomy<sup>26,27</sup> and the patient acceptance is higher.<sup>28,29</sup> Recurrence rates and reappearance of symptoms were equal to excision techniques.<sup>30,31</sup> A drawback is that the most important part of the operation has to be performed blindly. The high costs of the PPH stapler (400 Euro in Germany = 600 USD) makes this operation less attractive for the insurance companies. The technique described in this paper has the same advantages as the Longo procedure. The transanal open hemorrhoidopexy preserves the well-innervated hemorrhoidal tissue but no costly instruments are necessary. The anus did not need to be dilated as wide as in the Longo operation. The Parks retractor needed only a small opening to create a good field of vision. The Parks retractor was only opened to allow access for the instruments and was not used to stretch the anal sphincters and does not give a hidden "Lord effect." No postoperative fecal incontinence was observed. The resection of a small strip of mucosa was performed to prevent the hemorrhoidal tissue from slipping down when Vicryl sutures were dissolved at one month postoperation.

The postoperative pain generally observed in the PPH procedure made it necessary to keep the patients in the hospital for a few days in some reports.<sup>32,33</sup> The necessity of general anesthesia is questionable in this patient group. The results of this study indicate that it will be possible to perform the transanal open hemorrhoidopexy in the future as a day care procedure under local or regional anesthesia. The short operation time of 15 minutes is comparable with the 17 minutes in the Longo procedure.<sup>34</sup>

The postoperative residual prolapse was observed in two patients (5 percent) but could be managed conservatively and reoperation was not indicated.

As only an observational study, prospective, randomized studies are necessary to confirm the outcome of this

operation on the long-term basis and to confirm its value relative to other hemorrhoid treatments.

## CONCLUSION

The method of the transanal open hemorrhoidopexy seems to be an attractive alternative relative to other hemorrhoid tissue-preserving surgical techniques.

## REFERENCES

- Burkitt DP, Graham-Stewart CW. Hemorrhoids: postulated pathogenesis and proposed prevention. *Postgrad Med J* 1975; 51:631–6.
- Thomson H. A new look at hemorrhoids. *Med Times* 1976; 4:116–23.
- Thomson WH. The nature of hemorrhoids. *Br J Surg* 1975; 62:542–52.
- Corman ML. *Colon and rectal surgery*. 5<sup>th</sup> ed. Los Angeles: Lippincott Williams & Wilkins, 2005:177–8.
- Stelzner F, Staubesand J, Machleidt H. The corpus cavernosum recti-basis of internal hemorrhoids. *Langenbecks Arch Klin Chir Ver Dtsch Z Chir* 1962;299:302–12.
- Stelzner F. The corpus cavernosum recti. *Dis Colon Rectum* 1964;7:398–9.
- Davy A, Duval C. Modifications macroscopiques et microscopiques du reseau vasculaire hemorrhoidal dans la maladie hemorrhoidaire. *Arch Fr Appar Dig* 1976;65:515–21.
- Parnaud E, Guntz M, Bernard A, et al. Anatomie normale macroscopique et microscopique du reseau vasculaire hemorrhoidal. *Arch Fr Mal Appar Dig* 1976;65:501–14.
- Haas PA, Fox TA, Haas GP. The pathogenesis of hemorrhoids. *Dis Colon Rectum* 1984;27:442–50.
- Bleday R, Pena JP, Rothenberger DA, Goldberg SM, Buls JG. Symptomatic hemorrhoids: current incidence and complications of operative surgery. *Dis Colon Rectum* 1992;35:477–81.
- Ho YH, Buettner PG. Open compared with closed hemorrhoidectomy: meta-analysis of randomized controlled trials. *Tech Coloproctol* 2007;11:135–43.
- Morinaga K, Hasuda K, Ikeda T. A novel therapy for internal hemorrhoids: ligation of the hemorrhoidal artery with a newly devised instrument (Moricorn) in conjunction with a Doppler flow meter. *Am J Gastroenterol* 1995;90:610–13.
- MacRae HM, McLeod RS. Comparison of hemorrhoidal treatments: a meta-analysis. *Can J Surg* 1997;40:14–7.
- Ooi BS, Ho YH, Tang CL, Eu KW, Seow-Choen F. Results of stapling and conventional hemorrhoidectomy [letter]. *Tech Coloproctol* 2002;6:61–2.
- Longo A. Treatment of haemorrhoid disease by reduction of mucosa and haemorrhoid prolapse with a circular-suturing device: a new procedure. In: *Proceedings of the Sixth World Congress of Endoscopic Surgery*. Rome:1998;777–84.
- Beattie GC, Loudon MA. Follow-up confirms sustained benefit of circumferential stapled anoplasty in the management of prolapsing hemorrhoids. *Br J Surg* 2001;88:850–2.
- Correa-Rovelo JM, Tellez O, Obregon L, et al. Stapled rectal mucosectomy vs. closed hemorrhoidectomy. *Dis Colon Rectum* 2002;45:1367–74.
- Fazio VW. Early promise of stapling technique for hemorrhoidectomy. *Lancet* 2000;355:768–9.
- Ganio E, Altomare DF, Gabrielli F, et al. Prospective randomized multicentre trial comparing stapled with open hemorrhoidectomy. *Br J Surg* 2001;88:669–74.
- Ho Y-H, Cheong W-K, Tsang C, et al. Stapled hemorrhoidectomy: cost and effectiveness. Randomized, controlled trial including incontinence scoring, anorectal manometry, and endoanal ultrasound assessments at up to three months. *Dis Colon Rectum* 2000;43:1666–75.
- Khalil KH, O'Bichere A, Sellu D. Randomized clinical trial of sutured versus stapled hemorrhoidectomy. *Br J Surg* 2000; 87:1352–5.
- Mehigan BJ, Monson JR, Hartley JE. Stapling procedures for hemorrhoids versus Milligan-Morgan hemorrhoidectomy: a randomized controlled trial. *Lancet* 2000;355:782–5.
- Pernice LM, Bartulucci B, Bencini L, et al. Early and late (ten years) experience with circular stapler hemorrhoidectomy. *Dis Colon Rectum* 2001;44:836–41.
- Ganio E, Altomare DF, Gabrielli F, Milito G, Canuti S. Prospective randomized multicentre trial comparing stapled with open hemorrhoidectomy. *Br J Surg* 2001;88:669–74.
- Shalaby R, Desoky A. A randomized clinical trial of stapled versus Milligan-Morgan haemorrhoidectomy. *Br J Surg* 201; 88:1049–53.
- Corea-Rovelo JM, Telez O, Obregon L, Miranda-Gomez, Moran S. Stapled rectal mucosectomy vs. closed hemorrhoidectomy: a randomized, controlled trial. *Dis Colon Rectum* 2002;45:1367–74.
- Ortiz H, Mazo J, Armendariz P. Randomized clinical trial of stapled (circular) vs. conventional diathermy hemorrhoidectomy. *Br J Surg* 2002;89:1376–81.
- Bikhchandani J, Agarwal PN, Kant R, Malik VK. Randomized controlled trial to compare the early and mid-term results of stapled versus open hemorrhoidectomy. *Am J Surg* 2005;189: 56–60.
- Gravie JF, Lehur PA, Hutten N, et al. Stapled hemorrhoidopexy versus Milligan-Morgan hemorrhoidectomy: a prospective, randomized, multicenter trial with 2-year postoperative follow-up. *Ann Surg* 2005;242:29–35.
- Cheetham MJ, Cohen CR, Kamm MA, Philipps RK. A randomized, controlled trial of diathermy hemorrhoidectomy vs. stapled hemorrhoidectomy in an intended day-care setting with longer-term follow-up. *Dis Colon Rectum* 2003;46: 491–7.
- Racalbuto A, Aliotta I, Corsaro G, Lanteri R, Di Cataldo A, Licata A. Hemorrhoidal stapler prolapsectomy vs Milligan-Morgan hemorrhoidectomy: a long term randomized trial. *Int J Colorectal Dis* 2004;19:239–44.
- Tjandra JJ, Han WR. Anal anesthetic block significantly reduces immediate postoperative pain after stapled hemorrhoidectomy [meeting abstract]. *Dis Colon Rectum* 2004;47: 607.
- Kairaluom M, Nuorva K, Kellokumpo I. Day-case stapled (circular) vs. diathermy hemorrhoidectomy: a randomized controlled trial evaluating surgical and functional outcome. *Dis Colon Rectum* 2003;46:93–9.
- Tjandra JJ, Chan MK. Systematic review on the procedure for prolapse and hemorrhoids (stapled hemorrhoidopexy). *Dis Colon Rectum* 2007;50:878–92.